

**Neoplasia II: Benign and malignant neoplasms in squamous epithelium and haematopoietic tissue**

**1.0. Aims**

1. To study the multistep development of cervical neoplasms
2. To develop an understanding of metaplasia: what it is and where it occurs.
3. To recognise Cervical Intraepithelial Neoplasia (CIN) as a pre-malignant neoplasm in the CIN-carcinoma sequence.
4. To identify invasion as evidence of malignancy in a squamous carcinoma of the cervix uteri.
5. To see an important example of cytopathological screening for neoplasia
6. To examine an example of a neoplasm caused by virus infection
7. To see other examples of squamous epithelial tumours from skin
8. To examine different types of leukaemia (haematopoietic system neoplasia)

**2.0. Cervical neoplasia**

Cervical cancer is one of most prevalent cancers worldwide and it is socially and economically important. It illustrates several aspects of neoplasia well:

- The multistage development of neoplasms
- Metaplasia and the progression to neoplasia
- The role of infectious agents in some neoplasms
- Screening by cytopathological detection of pre-cancerous neoplastic cells

**2.1. Squamous epithelial neoplasms and metaplasia**

Both benign and malignant neoplasms can arise from any area of squamous epithelium. This includes not only the epidermis of the skin, but also the internal surfaces which are normally lined by squamous epithelium.

Q1 Can you think of some? (Think about the Gastro-Intestinal Tract).

There are also other important sites where squamous cell carcinomas can arise, perhaps unexpectedly at first sight as these sites are not initially lined by squamous epithelium. This is because it follows a change in the epithelial differentiation programme, known as metaplasia, which usually occurs as a response to injury. In such circumstances, tough, multi-layered squamous epithelium is particularly suited to replace more delicate, specialised single-layered epithelium and does so quite frequently. Metaplastic change to squamous epithelium is a response to chronic injury and as such has an increased turnover rate, quite apart from other molecular differences which may be present.

<b>Term</b>	<b>Meaning</b>	<b>Normal or abnormal?</b>	<b>Example</b>
<b>Hyperplasia</b>	increased cell number	either	normal in breast in pregnancy; abnormal hyperplasia can be an early precursor of neoplasia
<b>Metaplasia</b>	change of differentiated cell type	either: often a normal response to injury	squamous metaplasia of endocervix (from glandular epithelium); squamous metaplasia of bronchus (from respiratory pseudostratified epithelium); intestinal metaplasia in stomach (from gastric glandular epithelium to intestinal goblet cell epithelium)
<b>Dysplasia</b>	abnormal growth pattern with features of benign neoplasia (no invasion)	abnormal	CIN 3 in cervix (see below) – pleomorphic & hyperchromatic nuclei with mitoses above the basal layer (no invasion); squamous dysplasia in the bronchus; glandular dysplasia in colorectal adenomas or gastric adenomas

We shall look at an example of squamous metaplasia in the uterine cervix, and follow a possible course of evolution through a premalignant dysplastic stage called Cervical Intraepithelial Neoplasia (or CIN) to an invasive squamous carcinoma (this is the CIN-carcinoma sequence).

### 2.1.1. Normal Adult Cervix

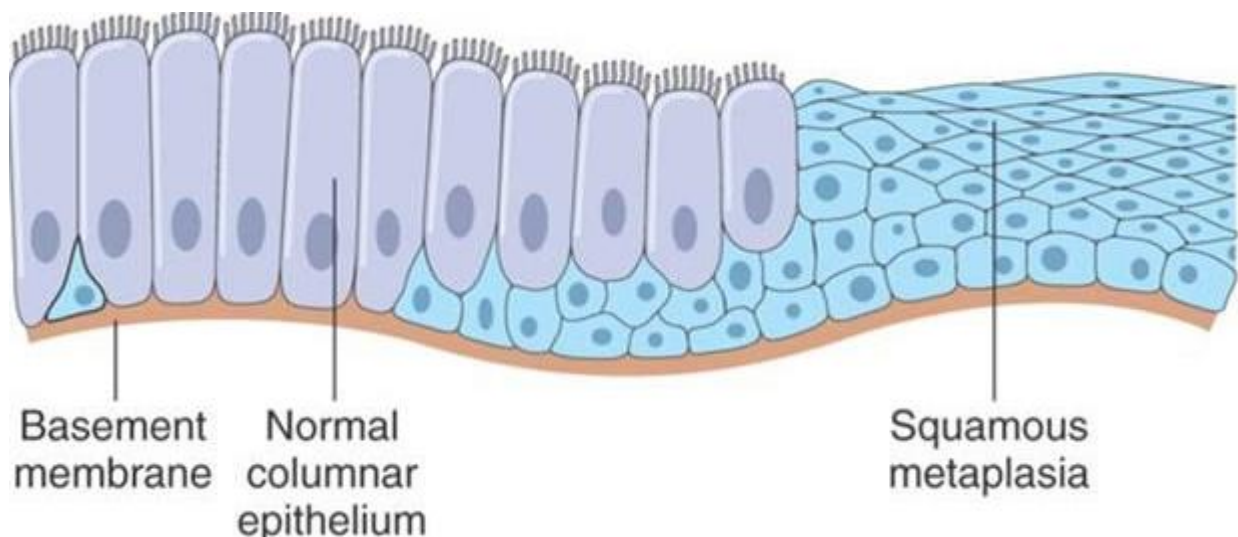
**NDP Images:** UG7: [82.74](#); [87.1081](#)

**Glass Slides:** UG7: [82.74](#); [87.1081](#)

(latter shows one side of endocervical canal only)

**Image Map:** [N UR CX 02](#); [N UR CX 11](#)

Find the **squamo-columnar junction**, which is where the single-layered, **columnar** glandular **epithelium** that lines the endocervical canal of the uterus meets the squamous epithelium of the ectocervix (the part that projects into the vagina). Note how sharp and distinct the boundary can be. The region of the cervix where the squamo-columnar junction occurs is often known as the **transformation zone**.



### 2.1.2. Endocervix: squamous metaplasia

**NDP Images:** [24.1: 87.1210 \(H&E stain\)](#)  
[24.2: 87.1210 \(Alcian Blue stain\)](#)  
**Glass Slides:** **24.1: 87.1210 (H&E stain)**  
**24.2: 87.1210 (Alcian Blue stain)**

You are given both an H&E stained slide and a scan of a duplicate stained with Alcian Blue to show mucin.

This tissue represents the lining of the cervix uteri at the transformation zone. As the uterus grows in size around and after puberty, the cervix expands outwards bringing some columnar glandular epithelium (originally from the endocervical canal) onto the ectocervical surface (around the os) and here it is exposed to the low pH vaginal environment. This zone is therefore subject to chronic irritation. As a result, there is often a change from the normal mucus-secreting glandular epithelium, which consists of a single layer of regular tall columnar cells with basal nuclei, to multi-layered squamous epithelium. This has happened in this example; over the surface there is extensive squamous metaplasia at the transformation zone.

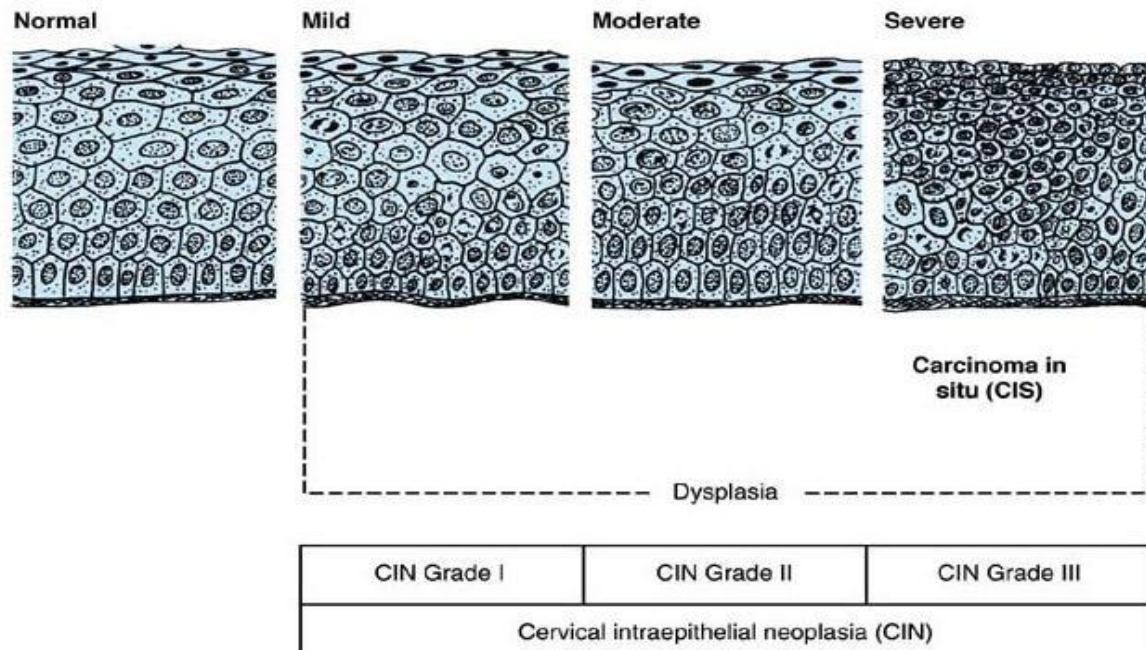
The Alcian Blue stain helps to distinguish the columnar epithelium (stained blue for mucin) from the metaplastic epithelium (no mucin). In places you can see where the metaplastic epithelium has spread under the columnar epithelium.

Q2 Squamous metaplasia is common in the cervix uteri and in the respiratory tract. What is the most likely irritative cause in the bronchial tree?

### 2.2. Cervical intraepithelial neoplasia (CIN) can develop from metaplasia

The commonest form of cervical cancer is squamous carcinoma of the cervix which arises within metaplastic squamous epithelium. It often passes through premalignant stages before invasion occurs. These premalignant (or pre-invasive) stages are termed **Cervical Intraepithelial Neoplasia**, often shortened to CIN. CIN can vary in severity of the neoplastic change, from low grade or CIN 1 (where the neoplastic cells occupy the lower one third of the squamous epithelium, nearest to the basement membrane), through CIN 2 (two thirds occupation by neoplastic cells) to high grade or CIN 3 (full or 3/3 occupation by neoplastic cells). In older textbooks, you may see these changes referred to as dysplasia (for CIN 1 & 2) and carcinoma-in-situ (for CIN 3); these terms are no longer used for neoplasms of the cervix, although they are still used for similar lesions elsewhere, such as in the bronchus. In the USA, the term Squamous Intraepithelial Lesion (SIL) is used and is split into Low Grade SIL (LSIL) and High Grade SIL (HSIL). However, as this term has only 2 subcategories and refers to a "lesion"—and thus does not specify that the abnormality is a neoplasm—it is considered less informative compared with CIN (with 3 subcategories), and thus use of CIN is preferred in the UK (although both systems of nomenclature may be used).

See diagram of CINI-III added to slide folder as an image file.



### 2.2.1. Uterine cervix: CIN 3

**NDP Images:** [24.3: 80.224](#)

**Glass Slides:** 24.3: 80.224

**Image Map:** [A NP CU CX 04](#)

This section of cervix includes an area of **CIN 3** which is confined **within the epithelium** (no invasion through the basement membrane under the epithelium), even though you can see that it extends downwards into the endocervical glands. (Note that this is the same distribution as the squamous metaplasia in the previous sections).

The CIN 3 looks much darker than the normal non-keratinised ectocervical epithelium which is present at one end of the tissue section. This is because there is full-thickness occupation of the epithelium by far more nuclei (which are often larger and more darkly staining than normal); the cells are abnormally orientated, often appearing to stream towards the surface; and there are mitotic figures at all levels of the epithelium (in normal squamous epithelium only the basal layer contains mitotic figures).

After the discovery of abnormal cells in the cervical smear of a 39 year old woman, her uterus was removed and these changes were found.

Q3. Can you see evidence of loss of normal proliferative controls in CIN 3?

There is a pathway of progression from normal endocervical glandular epithelium to squamous metaplasia, to CIN. From within high grade CIN 2 or CIN 3 lesions, a malignant clone may evolve to invade through the basement membrane to form an invasive squamous cell carcinoma.

## 2.3. Invasive squamous cell carcinoma (cervix)

### 2.3.1. Uterine cervix: Invasive squamous cell carcinoma

**NDP Images:** [24.4: 82.194](#)

**Glass Slides:** 24.4: 82.194

**Image Map:** [A NP CA CX 13](#)

This slide was prepared from the resected uterus of a 47 year old woman who had never had a cervical smear screening examination, but already **had invasive carcinoma** by the time she presented to her doctor, having noticed some irregular vaginal blood loss.

Notice in particular that the carcinoma has invaded down from the epithelium deeply into the connective tissue stroma of the cervix, forming islands and tongues of cancer cells and some solid sheets of cancer cells. Around the deepest invasive edge, the carcinoma has invaded into some **lymphatic vessels**.

Q4 (a) Can you see evidence of invasion into the cervical stroma? (b) Is there a host response to invasion? (c) Why does this host response occur?

Q5 What features can you recognise to determine the pattern of differentiation of this neoplasm (and therefore its histogenesis)?

Q6 What are some possible sites of origin of squamous cell carcinomas?

Q7 (a) What is meant by CIN? (b) Is it non-invasive or invasive? (c) How would you recognize it histologically?

Q8 How do you define metaplasia?

Q9 What type of vessel do (a) carcinomas usually invade earliest? (b) sarcomas usually invade earliest?

Museum specimen [24.67](#) is from a woman of 48 years who had a blood stained discharge for eight months. The cervix is replaced and expanded by carcinoma (squamous cell carcinoma) which is itself eroded.

## 2.4. Cervical Screening

The cervix presents an ideal opportunity for cancer screening, because the precursors of cancer, CIN 1 to 3, are accessible, detectable and removable. Thus, it is possible to identify and remove many precursors before they become malignant—the most effective kind of screening. Cells are scraped from the surface of the cervix with a wooden/plastic spatula (or brush sometimes) and put on a glass slide (either by smearing the cells directly on to the slide to make a “cervical smear” or by washing the cells off the spatula and spinning them onto a slide [liquid-based cytology or LBC preparation], and examined cytologically. The abnormal neoplastic cells from pre-invasive CIN lesions can be recognized (as “dyskaryotic” cells with abnormal nuclei) and subsequently eradicated by treatment (surgical removal often with a hot wire loop). To be effective this screening procedure must be carried out as a regular, routine examination (usually every 3-5 years).



### 2.4.1. Cervical Cytology Specimens

**NDP Images:** [24.5](#) and [24.6](#)

The scanned image of LBC slide [24.5](#) shows normal squamous cells scraped from the cervix, with superficial cells having pink cytoplasm and intermediate cells having a green/blue cytoplasm, both with small, bland, oval nuclei; whereas LBC slide [24.6](#) shows neoplastic cells from CIN 3, illustrating the abnormal enlarged, pleomorphic and hyperchromatic nuclear appearances seen in cervical liquid-based cytology of CIN 3 cells (nuclear atypia is called "dyskaryosis" when seen in single cells in cytological preparations, but is regarded as part of "dysplasia" in histological sections where the architecture can be analysed). (Hint: look at the cells or cell clusters between the coloured dots.)

### 2.5. Human Papillomaviruses (HPV) & neoplasms of the cervix

Cancer of the cervix is one of the human cancers strongly associated with an infectious agent, and an important example in the developed world. Almost all cervical carcinomas contain a high-risk Human Papillomavirus such as HPV 16 or HPV 18. The virus infects the metaplastic epithelium and following persistent infection with high risk HPV there may be development of CIN. HPV can be detected in sections of cervical neoplasms by in-situ hybridisation, i.e. hybridisation of labelled DNA probes to HPV DNA in the section, as illustrated in the next slide.

#### 2.5.1. In-situ hybridisation for Human Papillomavirus HPV16 DNA in a CIN 1 lesion

**NDP Image:** [24.7](#)

Slide in which the presence of human papillomavirus nucleic acid has been detected by hybridising to a DNA probe (brown signal in the nuclei = hybridisation by labelled probe).

Transient genital HPV infections are very common in young sexually active women. Most are subclinical and resolve, with many lesions appearing as low grade CIN 1. A minority of women develop persistent infections, and if they are infected with high risk HPVs, the infected epithelium may gradually progress to CIN2/3 and in time to invasive carcinoma. The virus brings with it certain viral genes that stimulate cell proliferation, immortalization, reduce apoptosis and confer genetic instability, which provide some components of loss of growth control, and facilitate the acquisition of additional mutations that encourage the process of neoplastic progression.

### 2.6. Invasion

#### 2.6.1. Skin: invasive squamous cell carcinoma

**NDP Images:** [24.8: 59.574](#)

**Glass Slides:** 24.8: 59.574

**Image Map:** [A NP CA SK 31](#); [A NP CA SK 33](#)

This section of skin shows another example of an invasive squamous cell carcinoma. Islands of tumour cells infiltrate through the dermis of the skin. The appearances of many of the islands shows keratinisation with formation of central keratin – bright

pink protein, in a pattern roughly similar to that seen in normal squamous epithelium of the skin, sometimes forming ovoid shapes with layers of keratin termed "keratin pearls". This is clear evidence of squamous differentiation in the tumour, indicating its squamous histogenesis.

This is a cross section of skin, from a 71-year-old man who developed a firm, crusty plaque on his ear.

## 2.6.2. Lymph node: metastatic squamous cell carcinoma

**NDP Images:** [24.9: 87.1120](#)

**Glass Slides:** 24.9: 87.1120

The two larger lymph nodes are extensively replaced by abnormal tissue in which there is deep pink laminated material, often arranged as whorls; this is **keratin** and it is immediately surrounded by large cells with features of neoplastic squamous cells. Some contain kerato-hyaline granules. At the edges of the epithelial areas, the cells resemble the basal cells of the skin but have nuclei that are quite pleomorphic and contain frequent mitotic figures. The appearance is that of metastases of well differentiated or **keratinising squamous carcinoma**. The primary tumour was present in the area drained by these nodes, for example in the neck where nodes drain the region including the ear and this might represent spread from the ear skin squamous cell carcinoma of the previous case.

Museum specimen [43.339](#) is from a 45 year old man with a 5 month history of cough, breathlessness and chest pain. A squamous cell carcinoma arising, as in the cervix, from a columnar epithelium that has converted by metaplasia to squamous epithelium. The bronchial mucosa is nodular; much of the wall is destroyed by squamous cell carcinoma, which has spread to lymph nodes; the large node below the carina is necrotic. There are distended bronchi distal to the obstruction; some containing inspissated secretion and organising pleurisy is seen over the collapsed and consolidated lower lobe. Persistent infection may draw attention to underlying carcinoma of the lung.

Museum specimen [37.162](#) is an example of a squamous cell carcinoma that arises from a normally squamous epithelium without metaplasia. A large carcinoma of the lower oesophagus with metastasis to a lymph node.

Museum specimen [26.124](#) is an example of a squamous cell carcinoma behind the ear that is undergoing central ulceration.

Museum specimen [26.129](#) is from a 56 year old woman with a squamous cell carcinoma of the cervix. The tumour has spread from the cervix into the body of the uterus.

Museum specimen [P80.869](#) is from a 69 year old man who had been coughing and breathless for a few months. The site of origin of the squamous cell carcinoma cannot be seen but it is wrapped around the main bronchi and has spread to the lymph nodes, (look at the back of the pot).The enlarged nodes compress the innominate artery and veins are thrombosed.

Museum specimen [27.67](#) is a Teratoma, a tumour of germ cells and some, particularly the benign ones, are remarkable for their ability to differentiate into all kinds of tissues (those tissues normally derived from the endoderm, mesoderm and ectoderm

in the embryo), emulating embryonic development. This specimen is a large cyst formed by a benign teratoma, which has developed many different tissue types including skin, hair and teeth. Note that it remains enclosed without invasion — it is benign. A scan of a section through the teratoma, case 58.0318, is provided for the curious.

### 3.0. Leukaemia

Leukaemias and lymphomas are neoplasms of the haematopoietic system. Leukaemias result in large numbers of neoplastic white blood cells in the blood (leuk- means 'white' and -aemia means 'blood'), whereas lymphomas are solid tumours of neoplastic lymphocytes (mainly in lymph nodes and sometimes in other sites). Both cause disease usually by interfering with normal bone marrow and/or lymphocyte function, as well as spreading to other organs, as illustrated in the museum specimens below. All leukaemias are considered to be **malignant** neoplasms. Leukaemias are broadly classified as:

(i) **lymphoid** or **myeloid**, according to the cell lineage. Lymphocytic or lymphoid means derivation from the lymphocyte lineage, including lymphocyte precursors; the myeloid lineage is essentially everything else, including neutrophils and other granulocytes, monocytes, erythrocytes and platelets – see diagram below.

(ii) **acute** or **chronic**, according to their behaviour and cellular appearance. Acute leukaemias tend to grow and progress fast, and the neoplastic white blood cells appear undifferentiated (with large nuclei often described as "blast" cells); chronic leukaemias tend to be more indolent and slow growing, and the cells are usually more differentiated, showing similar appearances to fully differentiated normal counterparts. Hence, there are 4 major categories: chronic myeloid leukaemia (CML; known for its BCR-ABL chimeric gene due to the t(9;22) Philadelphia chromosome translocation), acute myeloid leukaemia (AML), chronic lymphocytic leukaemia (CLL) and acute lymphocytic leukaemia (ALL, the commonest childhood leukaemia).

Examine the scanned images of the three slides of leukaemias, which represent one acute and two types of chronic leukaemia. Note the relatively high ratio of leucocytes to red cells in these smears, compared to normal (slide H1). Compare the size of the white cells with the red blood cells. (There are many ruptured / lysed cells displaying "burst open nuclei" – ignore these artefacts).

#### 3.1. Blood smears: leukaemias

**NDP Images: 24.10-24.12:**

[24.10: 96.346](#); [24.11: 96.357](#); [24.12: 68.138](#)

[H1: 86.547: Normal blood smear for reference](#)

Q10 Try to classify these leukaemias using the degree of differentiation of the cells [large undifferentiated blast cells (acute) OR well differentiated cells similar to normal leucocytes (chronic)] and the cell types [lymphocytic/lymphoid or myeloid]?

Museum specimen **80.525** is a bladder from a 15-year-old girl who died of acute leukaemia, which caused haemorrhage. The black material is clotted blood. This is an example of how leukaemia can result in failure of the bone marrow due to suppression



of cell production, generating reduced platelets in the blood, leading to a tendency to bleed uncontrollably and eventually death.

Museum specimen [77.611](#) is a leg bone from a leukaemia case. Note how the brown, cellular marrow has expanded to occupy almost all the bone, in contrast to the normal bone (next specimen – 86.114) where most of the marrow contains adipose tissue.

Museum specimen [55.458](#) is a spleen which has been infiltrated and expanded by large numbers of leukaemia cells (and which is only a slice of the whole organ); compare with the following normal spleen (83.614 or 84.470). This gives an indication of how extensive the population of leukaemic cells had become in this patient.

#### 4.0 Unknown slide: Stomach

**NDP Image: [24.13: 84.313](#)**

**Glass Slide: 24.13: 84.313**

This section is from the stomach of a patient complaining of upper abdominal discomfort and weight loss of 2 stones.

Q11 Sketch the appearances and describe the main features present in this section, then identify the pathological process and give a diagnosis.

Q12 Why might this disease often be fatal?

#### 5.0. Some words used in the neoplasia practicals

-plasm	Formative substance	
-plasia	Growth process	
Neo-	New	Neoplasm = new growth (tumour mass)
		Neoplasia = new growth (process)
Meta-	Beyond / above / in place of	Metaplasia = one cell type growing in place of another (NOT neoplastic)
Dys-	Abnormal / bad	Dysplasia = abnormal growth of neoplastic cells (used to describe benign or non-invasive epithelial tumours)
Differentiation	Differ = unlike, distinct or various	Differentiation = growth pattern of different or specialized function (used to describe malignant tumours) Well-differentiated = tumour growth pattern VERY SIMILAR to tissue of origin Poorly-Differentiated = tumour growth pattern VERY DIFFERENT to tissue of origin (but still recognizable as tissue of origin)
Ana-	Without / opposite to	Anaplasia = tumour growth WITHOUT a clear growth pattern (unlike any tissue of

		origin)
-oma	Swelling or mass	Can be non-neoplastic or neoplastic
Haem-	Blood	Haematoma = swelling due to blood (bruise)
Aden-	Glandular	Adenoma = benign neoplasm of glandular epithelium
Carcinoma	Malignant epithelial tumour	Adenocarcinoma = malignant tumour of glandular epithelium
		Squamous Carcinoma = malignant tumour of squamous epithelium
Myo-	Muscle	
Leio-Myo-	Smooth Muscle	Leiomyoma = benign smooth muscle cell tumour
Sarcoma	Malignant mesenchymal tumour	Leiomyosarcoma = malignant smooth muscle cell tumour
Rhabdo-Myo-	Striated Muscle	Rhabdomyoma = benign striated muscle cell tumour Rhabdomyosarcoma = malignant striated muscle tumour
Osteo-	Bone	Osteoma = benign bone tumour Osteosarcoma = malignant bone tumour
Fibro-	Fibroblast / fibrous tissue	Fibroma = benign fibroblastic tumour Fibrosarcoma = malignant fibroblastic tumour
Chondro-	Cartilage	Chondroma = benign cartilaginous tumour Chondrosarcoma = malignant cartilaginous tumour
Lipo-	Fat	Lipoma = benign fat tumour Liposarcoma = malignant fat tumour
Nucleus	Small nut, (nux=nut)	
Pleo-	Many / more / variation	
Morphe	Form	Pleomorphism = variation in nuclear size, shape and chromatin staining pattern
Hyper-	Increased	