

Pathology Practical Class 23

NEOPLASIA I: Benign and malignant neoplasms in glandular epithelium and mesenchyme**AIMS**

1. To understand the distinction between benign and malignant neoplasms
2. To understand the nomenclature for neoplasms, based on benign versus malignant and tissue of origin (histogenesis)
3. To study multistage development of glandular epithelial neoplasia in the colon
4. To study invasion and metastasis
5. To consider presentation and screening
6. To study benign and malignant neoplasms of mesenchyme

BENIGN VERSUS MALIGNANT

The most important feature of a neoplasm is whether it is **benign** or **malignant**. Malignant tumours are capable of invasion and metastasis, i.e. spreading to other tissues, whereas benign tumours do not invade and cannot metastasize. This is crucial for the patient, since it is usually metastases rather than primary tumours that kill. We do not yet understand mechanistically what it is that makes a cell malignant, but benign and malignant tumours can be distinguished by their histological appearances as illustrated by the slides of colorectal epithelial neoplasms and uterine smooth muscle neoplasms.

CLASSIFICATION, HISTOGENESIS AND NOMENCLATURE

Solid tumours are classified according to whether they are benign or malignant, but also by their **histogenesis** (cell or tissue of origin). Benign tumours are often called [tissue]-oma, e.g. lipoma (fat cell benign tumour), leiomyoma (*leio*-smooth, *myo*-muscle benign tumour), adenoma (glandular tissue benign tumour). A glossary of these words is provided at the end of the sheet. Malignant epithelial tumours are mostly called [tissue] carcinoma or [tissue] adenocarcinoma (if from glandular epithelial tissue) e.g. colorectal adenocarcinoma. Malignant connective tissue tumours are mostly called [tissue]-sarcoma, e.g. liposarcoma (fat cell malignant tumour) or leiomyosarcoma (*leio*-smooth, *myo*-muscle malignant tumour). The common malignant tumours in humans are mostly carcinomas or adenocarcinomas.

Tumours of Epithelium:

Tissue	Benign	Malignant
Glandular epithelium	Adenoma	Adenocarcinoma
Squamous epithelium	Papilloma	Squamous Carcinoma

Tumours of Connective Tissues / Mesenchyme:

Tissue	Benign	Malignant
Fibrous tissue	Fibroma	Fibrosarcoma
Bone	Osteoma	Osteosarcoma
Cartilage	Chondroma	Chondrosarcoma
Fat	Lipoma	Liposarcoma
Smooth muscle	Leiomyoma	Leiomyosarcoma
Striated muscle	Rhabdomyoma	Rhabdomyosarcoma

COLORECTAL CANCER

Colorectal neoplasia is one of the commonest and best understood cancers. It illustrates well:

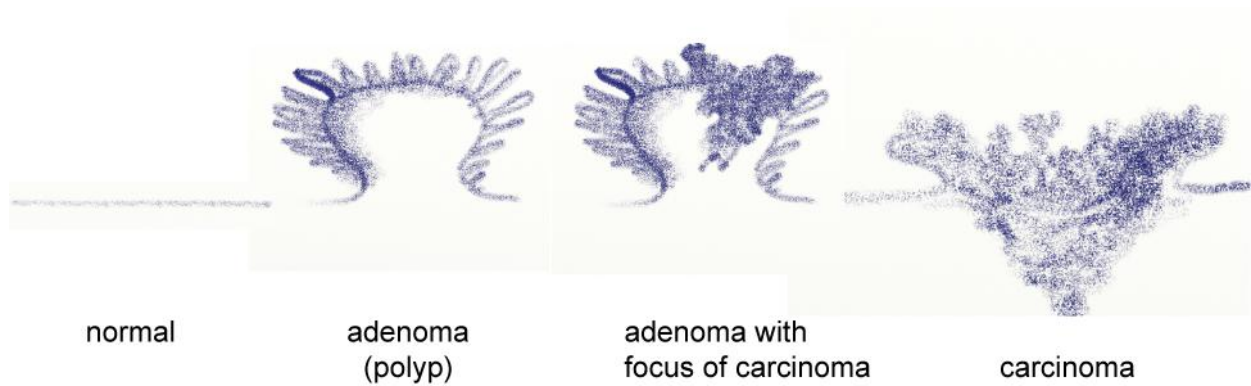
- The multistage development of neoplasms
- The difference between benign and malignant neoplasms
- Spread of cancer to other organs, leading to death
- The early detection of cancer or its precursors and possible screening strategies
- The molecular basis of cancer (which we will explore in Practical 25).

Colorectal neoplasia comprises colonic and rectal adenoma (benign) and adenocarcinoma (malignant).

MULTISTAGE DEVELOPMENT

Cancers develop by accumulating genetic and epigenetic changes that alter the behaviour of the cell. On the way to becoming a cancer, a neoplasm therefore passes through various abnormal precursor states, some of which we can recognize by their microscopic appearances. Early on an abnormal proliferation of cells in the glandular epithelium of the colon often forms a 'polyp' (polyp is a descriptive term [not a diagnosis] and refers to

a head of abnormal cells on a stalk). If the abnormal cells are a benign (non-invasive) neoplasm, it is called an adenoma or adenomatous polyp. Somewhere in this adenomatous polyp a fully malignant clone may eventually develop, which will gradually take over and grow down into the underlying tissue. This is called an adenocarcinoma.



We will look at four stages: an adenomatous polyp; an adenomatous polyp with a focus of invasive adenocarcinoma in it, where an adenoma cell has converted to malignancy; an established primary adenocarcinoma invading into the bowel wall; and finally a metastasis to the liver.

23.1 Colon: Adenoma - a benign precursor of cancer - diagram overleaf 77.270

Catalogue Number	Small Image	Image Map	Large Image
A_NP_PQ_LI_01.jpg	Colon - Adenoma		Colon - Adenoma
A_NP_PQ_LI_09.jpg	Colon - Adenoma		Colon - Adenoma
A_NP_PQ_LI_07.jpg	Colon - Adenoma	Image map	Colon - Adenoma

Excessive unregulated proliferation of the columnar epithelium has given rise to a **polyp** of branching, tubular pattern on a stalk of normal mucosa. The polyp behaves like a lump that peristalsis tends to pull down the gut, dragging out the normal wall to form the stalk. This is an **adenoma** or **adenomatous polyp** (polyp = head on a stalk). An example is shown in museum specimen I.

The cells of the adenoma are taller, more crowded and contain less mucin than the normal cells, i.e. have lost some differentiated features. The nuclei are seen towards the base of the cells, but show variation in nuclear size, shape and chromatin staining pattern (**pleomorphism**) and stain darkly (**hyperchromasia**). A small number of mitotic figures can be seen. However, this is a benign growth: there is **no invasion** through the muscularis mucosae into the stalk.

23.2 Colon: Transition to malignancy – a focus of adenocarcinoma developing in an adenoma - diagram overleaf 80.280

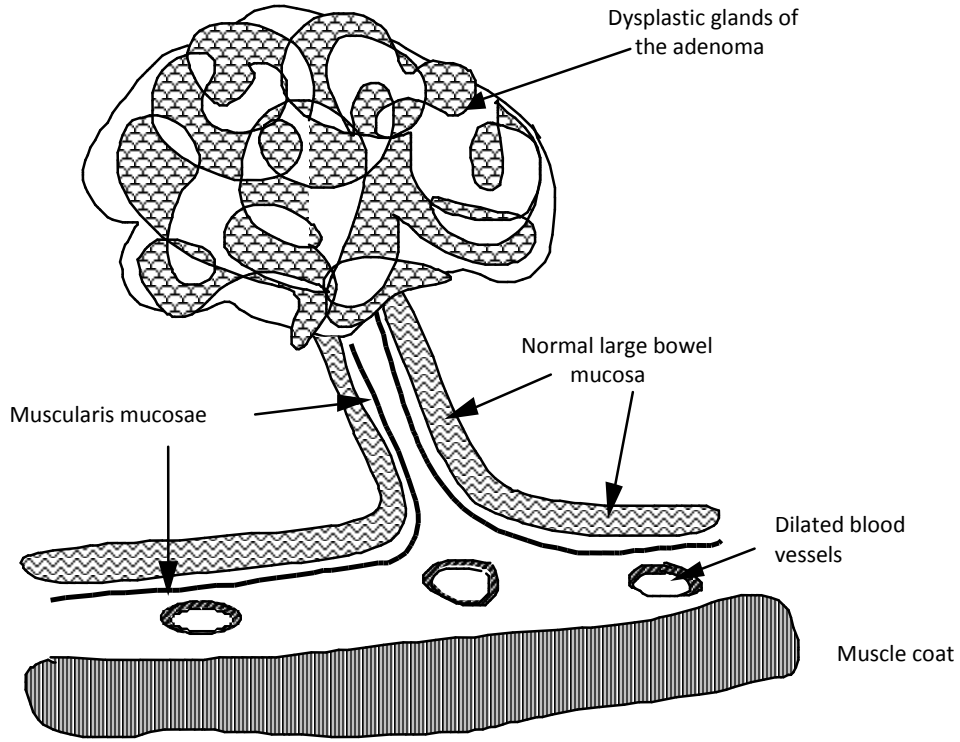
Catalogue Number	Small Image	Image Map	Large Image
A_NP_CA_LI_11.jpg	Colon - Adenocarcinoma	Image map	Colon - Adenocarcinoma
A_NP_CA_LI_13.jpg	Colon - Adenocarcinoma		Colon - Adenocarcinoma
A_NP_CA_LI_14.jpg	Colon - Adenocarcinoma		Colon - Adenocarcinoma

This slide is best understood by reference to the diagram below. Most of it is adenoma, like the preceding example, with a short stalk of normal mucosa at the bottom, but it has a focus of invasive malignant cells in the top centre, a cancer arising from a cell in the adenoma. Even the adenoma part shows more severe (high grade) dysplasia than the preceding example: the glandular pattern is **more complex** and the cells are taller, more densely packed and the epithelium looks darker because many of the nuclei are larger and more hyperchromatic.

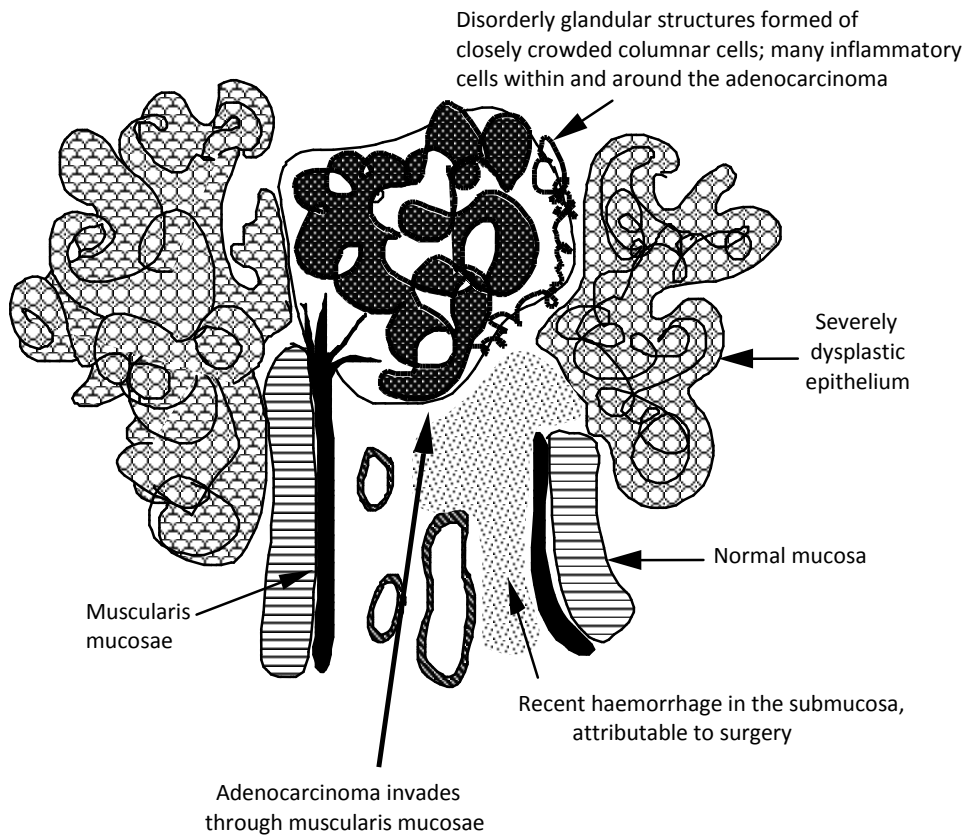
The cells in the centre of the polyp show signs of malignancy. They are no longer part of an epithelial sheet resting on a basement membrane, however elaborately folded, but are chaotic, and they are spreading or **invading** down into the stalk (having invaded through the basement membrane and through the muscularis mucosae). The cells show even more pronounced morphological features of neoplasia: they have a greater increase in nuclear/cytoplasmic ratio (bigger nuclei), greater pleomorphism and hyperchromatism, with little or no evidence of mucin storage. Mitotic figures can be seen quite easily. The gland-like structures appear as disorganized islands with irregular lumens and there is some epithelial budding into the lumens.

Consider the relationship of this central area to the normal tissue. Note that the muscularis mucosae which underlies the normal mucosa is frayed and split beneath the central area and that the budding glandular structures have penetrated it. A clone of cells has acquired **invasive properties** and the result is a small focus of **adenocarcinoma** which is **invading through the muscularis mucosae into the stalk**.

Colon : Adenoma
77.270



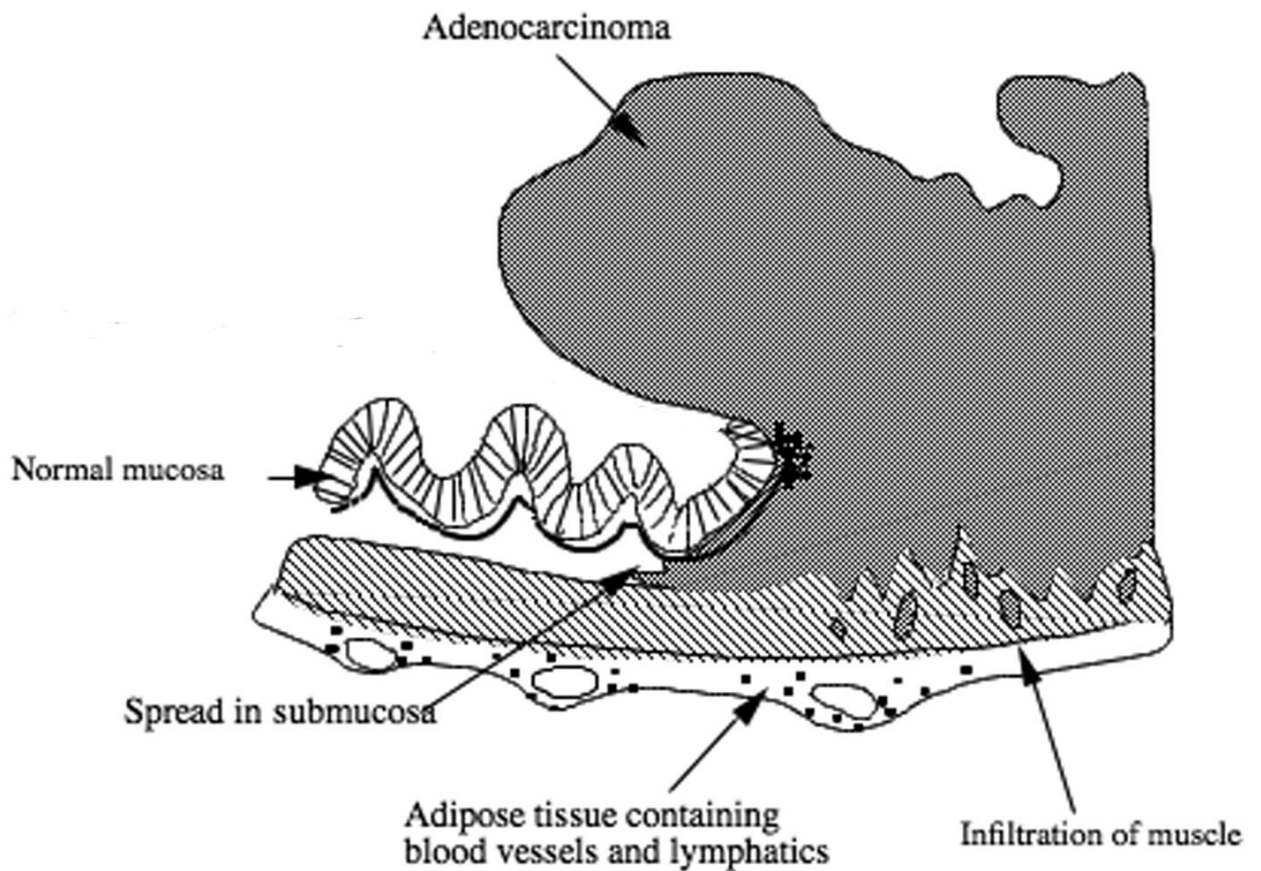
Adenocarcinoma developing from an adenoma
80.280



23.3 Colon: typical malignant tumour, an adenocarcinoma

71.663 B

Catalogue Number	Small Image	Image Map	Large Image
A_NP_CA_LI_18.jpg	Colon-adenocarcinoma	Image map	Colon-adenocarcinoma
A_NP_CA_LI_19.jpg	Colon-adenocarcinoma	Image map	Colon-adenocarcinoma
A_NP_CA_LI_20.jpg	Colon-adenocarcinoma	Image map	Colon-adenocarcinoma
A_NP_CA_LI_21.jpg	Colon-adenocarcinoma	Image map	Colon-adenocarcinoma



This is a colonic adenocarcinoma, clearly showing the malignant cells invading the underlying muscle and under the neighbouring normal epithelium. It is easy to imagine that it may have developed from a lesion like the preceding one, overgrowing it and gradually replacing the adenoma tissue.

Examine the tumour tissue and note how chaotic it is, but particularly zoom in to see the invasion marked in the diagram: the spread into the submucosa, under the adjacent normal epithelium, and infiltration into the muscle wall (muscularis propria) below the tumour. You should be able to see islands of cells forming ragged glandular structures, growing in between the muscle fibres. This is classical **malignant invasion**. Although we cannot yet see it, you can easily imagine that given time the malignant cells will reach beyond the muscle and also start to enter vessels, allowing dissemination around the body.

The cells in the tumour are glandular in type and are forming easily recognized glandular structures (the glandular spaces vary in shape and size). Therefore, it is a **moderately** differentiated adenocarcinoma. Many inflammatory cells are also present in the surrounding stroma which contains plump fibroblasts synthesising fibrous tissue, sometimes called a desmoplastic stroma.

Questions:

Q1. What is the significance of the occurrence of adenocarcinoma within an adenoma?

Q2. What do you think is the most significant difference in the behaviour of adenomas and adenocarcinomas?

Q3. What do you understand by the term moderately differentiated adenocarcinoma?

Q4. Which features in the adenocarcinoma section would help you in predicting the behaviour of this neoplasm?

METASTASIS

It is generally the spread or **metastasis** of cancer to other organs that causes illness (morbidity) and death (mortality). For example, spread to the liver, lung, brain or bone / bone marrow can prevent them from performing their normal functions.

23.4 Liver: spread of cancer to another organ, metastatic colonic adenocarcinoma in otherwise normal liver. 64-705

Catalogue Number	Small Image	Image Map	Large Image
A_NP_MT_LV_08.jpg	Liver – metastatic colonic adenocarcinoma in liver	Image map	Liver – metastatic colonic adenocarcinoma in liver
A_NP_MT_LV_06.jpg	Liver – metastatic colonic adenocarcinoma in liver	Image map	Liver – metastatic colonic adenocarcinoma in liver
A_NP_MT_LV_07.jpg	Liver – metastatic colonic adenocarcinoma in liver		Liver – metastatic colonic adenocarcinoma in liver

This slide shows metastasis from a primary colonic adenocarcinoma to the liver (commonly called secondary tumours or secondaries). Tumour cells from an adenocarcinoma such as the preceding one got into the circulation and have colonised other tissues, including liver, a common site of metastasis for colorectal cancers. The normal liver is made up of hepatocytes (with much pink cytoplasm and small nuclei) in plate-like structures surrounding sinusoids, central veins and portal triads. The tumour occupies most of the slide. It consists of irregular glandular structures, which have cells with very large nuclei and mitotic figures (compare tumour nuclei with adjacent hepatocyte nuclei). The tumour has a dense fibrous-tissue background (pale pink material). In the centre of the tumour there is bright pink material, which is a combination of dense fibrotic tissue, oedema fluid and necrotic tumour cells. Normal large arteries and bile ducts are trapped within the tumour.

Questions:

Q5. What are the routes of spread of metastasising adenocarcinoma of the large intestine?

Q6. Why is there necrosis within the tumour deposit?

PRESENTATION AND SCREENING STRATEGIES.

One reason why colorectal cancer can be fatal is that it is only discovered after it has metastasised. Colorectal cancer may **present** (i.e. the patient visits a GP to complain about a problem) in various ways. One is chronic bleeding, leading to anaemia. Look again at the adenocarcinoma slides and the museum specimens: the luminal surface is chaotic and ulcerated, which can lead to bleeding over a prolonged period of time. Another reason for presentation is obstruction of the bowel lumen leading to a change in bowel habit. Museum specimen **S61.2560** shows an example where fibrosis around the cancer has led to obstruction. Adenomas can also bleed or partially obstruct if large enough.

Two strategies are currently in use to attempt earlier detection by screening. One is testing for blood in
 teaching:DEPARTMENTAL TEACHING:Pt1:Practicals:2012-2013:P23_12-13:Handouts:P23_12-13v03asc

faeces, using the faecal occult blood test (FOBT). The other is endoscopy to find cancers early, but, even better, to find adenomas before they become malignant and remove them. What do you think the relative merits of these strategies might be?

GRADING OF MALIGNANT TUMOURS

Neoplastic cell nuclei are often enlarged, abnormal and variable (**pleomorphic**) in size, shape, and chromatin staining pattern, and this tends to be more pronounced in malignant cells than benign cells. Malignant cells often have nuclei that are darkly staining (**hyperchromatic**). There is disordered architecture with the relative positions and arrangements of tumour cells to one another often variable or abnormal, with more haphazard arrangements in malignant than benign neoplasms. The disordered architecture in glandular epithelial neoplasms may vary from well formed glands seen in some tumours to either poorly formed glandular lumina or solid sheets of tumour cells seen in other tumours. These features can be used to grade malignant tumours as either well differentiated (grade 1), if there are well formed glands with mild nuclear enlargement, pleomorphism and hyperchromasia, through moderate differentiation (grade 2), to poorly differentiated (grade 3), if there are mostly solid sheets with few glands with severe/marked nuclear enlargement, pleomorphism and hyperchromasia. These features together illustrate the aberrant growth patterns of neoplasms.

23.5 Breast: invasive adenocarcinoma

96.359

This section of breast tissue is composed of fatty tissue around the periphery and a central star-shaped region of dense fibrous tissue that contains an invasive adenocarcinoma. Within the stellate scar, there are variably sized clusters, irregular cords and islands of cancer cells with a surrounding fibrous (desmoplastic) stroma. More peripherally, the islands and tongues of tumour cells infiltrate outwards into the fatty connective tissue of the breast. At the left side of the section, there are areas of normal breast glandular tissue, with a duct and some breast lobules. In the centre of the breast cancer, there are a few dilated breast ducts containing neoplastic glandular cells (an example of the precursor – ductal carcinoma in situ). The appearances of some of the tumour islands show gland lumen formation with variable sizes and shapes of glandular lumina. Much of the tumour is formed of more solid-appearing cords and clusters of cancer cells. This gland formation represents clear evidence of glandular differentiation in the tumour, indicating its glandular (adeno-) histogenesis. This represents an example of a commonly occurring adenocarcinoma and its benign precursor in a different tissue, breast glandular epithelium, where the precursor-to-cancer sequence can be summarised as: **ductal carcinoma in situ – to - adenocarcinoma**. Breast cancers such as this can spread by lymphatic metastasis to local lymph nodes in the axilla (armpit) and by haematogenous metastasis to lung, liver, bone or other sites.

MESENCHYMAL TUMOURS

You have seen the contrast between the benign *adenoma* and malignant *adenocarcinoma* in a glandular epithelium. To see another, rather different, comparison of a benign and a malignant tumour, this time in a mesenchymal / connective tissue, compare the next two slides.

Benign and malignant smooth muscle tumours of the uterus

The contrast between a benign and a malignant tumour in the same tissue can be seen in uterine muscle wall. Compare a leiomyoma, a benign smooth muscle tumour of the uterus, and its malignant counterpart, a leiomyosarcoma.

These slides illustrate how benign tumours are confined to their normal position in tissue and often can be quite easily separated from surrounding normal tissue. In contrast, malignant tumours are usually disorganized in three dimensions, with ragged invasive edges, and may be seen to have spread into, and through, neighbouring layers of tissue.

23.6A Image and museum specimen: Uterus with multiple fibroids

S77.4368 and 4349 – (See Museum specimen)

Leiomyomas of the uterus are very common benign tumours often referred to as fibroids. A macroscopic image of a uterus with multiple leiomyomas is shown in the photograph. Note that the tumours are distinct, round, circumscribed bodies in the uterine wall with a whorled cut surface.

23.6B Myometrium: Leiomyoma, a benign smooth muscle tumour

58.521

Catalogue Number	Small Image	Image Map	Large Image
A_NP_TU_UT_10.jpg	Myometrium - Leiomyoma	Image map	Myometrium - Leiomyoma
A_NP_TU_UT_07.jpg	Myometrium - Leiomyoma	Image map	Myometrium - Leiomyoma

The section includes part of a leiomyoma, like the ones in the macroscopic picture. The tumour is a round ball of cells in a swirling pattern. It shows several features characteristic of a benign tumour, but the most important is that the tumour remains a **separate mass of cells, distinct and usually separated from the surrounding normal tissue**. Indeed in this example, shrinkage during tissue preparation has split the tissue along the junction between tumour and normal, emphasizing their separate nature. The tumour appears to have a distinct “capsule”, the connective tissue pressed into a layer over the expanding and slowly growing tumour. The benign smooth muscle tumour cells appear very similar to their normal counterparts in the surrounding tissue, with little nuclear pleomorphism and almost no mitotic figures.

23.7A Myometrium: Leiomyosarcoma, a malignant smooth muscle tumour 82.225

Catalogue Number	Small Image	Image Map	Large Image
A_NP_TU_UT_01.jpg	Myometrium - Leiomyosarcoma		Myometrium - Leiomyosarcoma
A_NP_TU_UT_03.jpg	Myometrium - Leiomyosarcoma	Image map	Myometrium - Leiomyosarcoma
A_NP_TU_UT_05.jpg	Myometrium - Leiomyosarcoma	Image map	Myometrium - Leiomyosarcoma

Malignant smooth muscle tumours arising in the uterine wall. Uterine leiomyosarcomas are much less common. Try and work out where the malignant cells and the normal cells are - it is much more difficult than in the benign tumour because the malignant cells are **invading into the surrounding normal** smooth muscle of the myometrial wall, and tongues of malignant cells are spreading between strands of normal muscle. This is the clearest sign that this tumour is malignant: it is not confined to a defined place but invades into surrounding tissues. The malignant smooth muscle tumour cells appear different their normal counterparts in the surrounding tissue, with marked nuclear enlargement and pleomorphism. Note that the leiomyosarcoma shows more nuclear pleomorphism than the leiomyoma (which shows very little nuclear pleomorphism). In fact, some of the leiomyosarcoma nuclei are very large and odd-looking or bizarre, forming so-called tumour giant cells. The leiomyoma nuclei are much more like those of normal smooth muscle cells. Mitotic figures are frequent in this leiomyosarcoma, while it is unlikely you will find mitoses in the leiomyoma.

23.7B Myometrium: Leiomyosarcoma stained with antibody to smooth muscle actin (96.306) (Scan only, no glass slides) R10.2424

Catalogue Number	Scanned Image
Myometrium: Leiomyosarcoma R10.2424 (96.306)	Myometrium: Leiomyosarcoma R10.2424 (96.306)

Malignant cells are more likely, in general, than benign tumours to be **less well differentiated** than normal cells. In the leiomyoma, the benign smooth muscle tumour cells are very similar to the normal ones, long and thin with plenty of muscle protein; while malignant cells of the leiomyosarcoma have less cytoplasm and don't seem to have as much muscle protein. In fact, sarcomas like this are often sufficiently poorly differentiated for a pathologist to find it difficult to identify their histogenesis (tissue or cell type of origin). However, they may still express enough of their characteristic proteins for antibody staining to solve the problem,

Slide R10.2424 (96.306) is a section from a leiomyosarcoma stained with either H&E or antibody to smooth muscle actin. This immunostain clearly identifies the cells as showing

features of smooth muscle differentiation, and a confident diagnosis of leiomyosarcoma can be made.

23.8 Photograph of a skin lipoma

Museum specimen 26.225

Catalogue Number	Small Image	Image map	Large image
A_NP_TU_SK_04.jpg	Skin: Lipoma (26.225)		Skin: Lipoma (26.225)
A_NP_TU_SK_05.jpg	Skin: Lipoma (26.225)		Skin: Lipoma (26.225)

This lipoma is a relatively common tumour in subcutaneous adipose tissue of skin. An example of a benign tumour of mesenchymal origin (fat cells). Note how the pathologist was able to easily separate the tumour from surrounding tissue.

CLASS 23 MUSEUM SPECIMENS

I COLON: ADENOMA

S61.5555

Catalogue Number	Small Image	Image map	Large Image
A_NP_PQ_LI_19.jpg	Colon - Polyp		Colon - Polyp

A polypoid tumour projecting into the lumen; there is no infiltration of the wall.

II RECTUM: ADENOCARCINOMA

00.349

Catalogue Number	Small Image	Image map	Large Image
A_NP_CA_LI_53.jpg	Rectum - Adenocarcinoma		Rectum - Adenocarcinoma

An ulcerated carcinoma with a raised edge abuts the anal margin, where there is also a haemorrhoid.

III COLON: ADENOCARCINOMA

S61.2836

Catalogue Number	Small Image	Image Map	Large image
A_NP_CA_LI_51.jpg	Colon- Adenocarcinoma		Colon - Adenocarcinoma

Muscular hypertrophy, proximal to a carcinomatous structure which almost occludes the sigmoid colon. The neoplasm extends through the muscle coat to invade the adjacent adipose mesocolon.

From a 64 year old man who complained of an intermittent griping abdominal pain and weight loss.

IV LIVER: METASTASES FROM ADENOCARCINOMA OF THE COLON

84.018

Catalogue Number	Small Image	Image map	Large Image
A_NP_MT_LV_15.jpg	Liver - Metastases		Liver - Metastases

The hepatic tissue shows fatty change and is stained green because of bile duct obstruction.

V COLON: ADENOMA**S61.3543**

Catalogue Number	Small image	Image map	Large image
A_NP_PQ_20.jpg	Colon - Polyp		Colon - Polyp

A polypoid tumour projecting into the lumen of the bowel.

VI COLON: ADENOCARCINOMA**S82.6709**

Catalogue Number	Small Image	Image map	Large Image
A_NP_CA_LI_54.jpg	Colon - Adenocarcinoma		Colon - Adenocarcinoma

Polypoid carcinoma of the colon which has ulcerated at the site where a block of tissue has been removed for histological examination.

Sigmoid colon removed from a man of 82 years with a change in normal bowel habit for two months.

VII COLON: ADENOCARCINOMA**S55.1643**

Catalogue Number	Small Image	Image map	Large Image
A_NP_CA_LI_52.jpg	Colon - Adenocarcinoma		Colon - Adenocarcinoma

An ulcerated carcinoma with characteristic raised edges, almost encircles the lumen. Viewed from the side, destruction of the muscle coat can be seen.

From a 79 year old man with a three month history of abdominal distension.

VIII COLON: ADENOCARCINOMA**S61.2560**

Catalogue Number	Small Image	Image map	Large Image

A_NP_CA_LI_55.jpg	Colon - Adenocarcinoma		Colon - Adenocarcinoma
-------------------	--	--	--

A constricting carcinoma of the ascending colon which has penetrated the muscle coat. Long standing obstruction has caused hypertrophy of the muscular wall of the proximal colon and terminal ileum. There are two small adenomatous polyps distal to the carcinoma.

From a 60 year old man who had suffered attacks of vomiting with intermittent constipation and diarrhoea during the previous year.

IX LIVER: METASTATIC CARCINOMA OF THE COLON

84.018

Catalogue Number	Small Image	Image map	Large Image
A_NP_MT_LV_16.jpg	Liver - Metastases		Liver - Metastases

As well as the metastatic deposit of tumour, there is fatty change in the hepatic parenchyma and green bile staining because of bile duct obstruction.

X COLON: FAMILIAL ADENOMATOUS POLYPOSIS

69.1477

Catalogue Number	Small Image	Image map	Large Image
A_NP_CA_LI_52.jpg	Colon - Adenocarcinoma		Colon - Adenocarcinoma

An ulcerated carcinoma with numerous adjacent adenomatous polyps.

XI BREAST: ADENOCARCINOMA

22.23

Catalogue Number	Small Image	Image Map	Large Image
A_NP_CA_BE_50.jpg	Breast -Adenocarcinoma		Breast -Adenocarcinoma

This is an old specimen and the adipose tissue has become rather dark. However it shows well an ill-defined greyish tumour in the breast, through which run yellow streaks of necrosis. The effect of the fibrous stroma is to draw in the nipple and pull on the underlying pectoral muscle where the carcinoma reaches it. From a 49 year old woman.

XII BREAST: ADENOCARCINOMA**S61.2405**

Catalogue Number	Small Image	Image map	Large image
A_NP_CA_BE_51.jpg	Breast -Adenocarcinoma		Breast -Adenocarcinoma

The breast contains an irregular pale tumour with yellowish streaks of necrosis on the surface. The slightly enlarged lymph nodes to which the carcinoma has spread, are included.

From a 66 year old woman who had noticed a little blood-stained discharge from the nipple.

XIII UTERUS: MULTIPLE LEIOMYOMAS**S77.4368 or 4349**

Catalogue Number	Small Image	Image map	Large image
A_NP_TU_UT_18.jpg	Myometrium-Leiomyoma (S77.4368)		Myometrium-Leiomyoma (S77.4368)
A_NP_TU_UT_19.jpg	Myometrium-Leiomyoma (S77.4349)		Myometrium-Leiomyoma (S77.4349)

This uterus is enlarged and distorted by multiple, roughly spherical benign leiomyomas. Note how clearly defined the tumours are. These are among the commonest tumours in humans.

XIV SKIN: LIPOMA**26.225**

Catalogue Number	Small Image	Image map	Large image
A_NP_TU_SK_04.jpg	Skin: Lipoma (26.225)		Skin: Lipoma (26.225)

An example of a benign tumour of mesenchymal origin. Note how the pathologist was able to easily separate the tumour from surrounding tissue. A relatively common tumour in subcutaneous adipose tissue.

SOME WORDS USED IN THE NEOPLASIA PRACTICALS

-plasm	Formative substance	
-plasia	Growth process	
Neo-	New	Neoplasm = new growth (tumour mass)
		Neoplasia = new growth (process)
Meta-	Beyond / above / in place of	Metaplasia = one cell type growing in place of another (NOT neoplastic)
Dys-	Abnormal / bad	Dysplasia = abnormal growth of neoplastic cells (used to describe benign or non-invasive epithelial tumours)
Differentiation	Differ = unlike, distinct or various	Differentiation = growth pattern of different or specialized function (used to describe malignant tumours) Well-differentiated = tumour growth pattern VERY SIMILAR to tissue of origin Poorly-Differentiated = tumour growth pattern VERY DIFFERENT to tissue of origin (but still recognizable as tissue of origin)
Ana-	Without / opposite to	Anaplasia = tumour growth WITHOUT a clear growth pattern (unlike any tissue of origin)
-oma	Swelling or mass	Can be non-neoplastic or neoplastic
Haem-	Blood	Haematoma = swelling due to blood (bruise)
Aden-	Glandular	Adenoma = benign neoplasm of glandular epithelium
Carcinoma	Malignant epithelial tumour	Adenocarcinoma = malignant tumour of glandular epithelium
		Squamous Carcinoma = malignant tumour of squamous epithelium
Myo-	Muscle	
Leio-Myo-	Smooth Muscle	Leiomyoma = benign smooth muscle cell tumour

Sarcoma	Malignant mesenchymal tumour	Leiomyosarcoma = malignant smooth muscle cell tumour
Rhabdo-Myo-	Striated Muscle (skeletal or cardiac)	Rhabdomyoma = benign striated muscle cell tumour Rhabdomyosarcoma = malignant striated muscle tumour
Osteo-	Bone	Osteoma = benign bone tumour Osteosarcoma = malignant bone tumour
Fibro-	Fibroblast / fibrous tissue	Fibroma = benign fibroblastic tumour Fibrosarcoma = malignant fibroblastic tumour
Chondro-	Cartilage	Chondroma = benign cartilaginous tumour Chondrosarcoma = malignant cartilaginous tumour
Lipo-	Fat	Lipoma = benign fat tumour Liposarcoma = malignant fat tumour
Nucleus	Small nut, (nux=nut)	
Pleo-	Many / more / variation	
Morphe	Form	Pleomorphism = variation in nuclear size, shape and chromatin staining pattern
Hyper-	Increased	
Chromatic	Colour	Hyperchromatism or hyperchromasia = increased darkness of nuclear colour staining

If you are not certain what is meant by any of the words used in these classes, please ask.