NST Part 1B **Fri 7th Oct. 2016**
Pathology Practical Class NHP2 **Introduction to Normal Histology 2**

1.0. Introduction

This is the second of two introductory classes that aim to familiarise you with the histological appearance of healthy tissues. These classes will make it easier for you to discover disease-associated changes for yourself later in the course.

2.0. Gastro-intestinal tract

The first four sections from this class are of tissues from the gastro-intestinal tract (GIT). While each region of the gastro-intestinal tract has a specific structure, all regions share basic structural features such as a 4-layered wall, as shown in the diagram below.

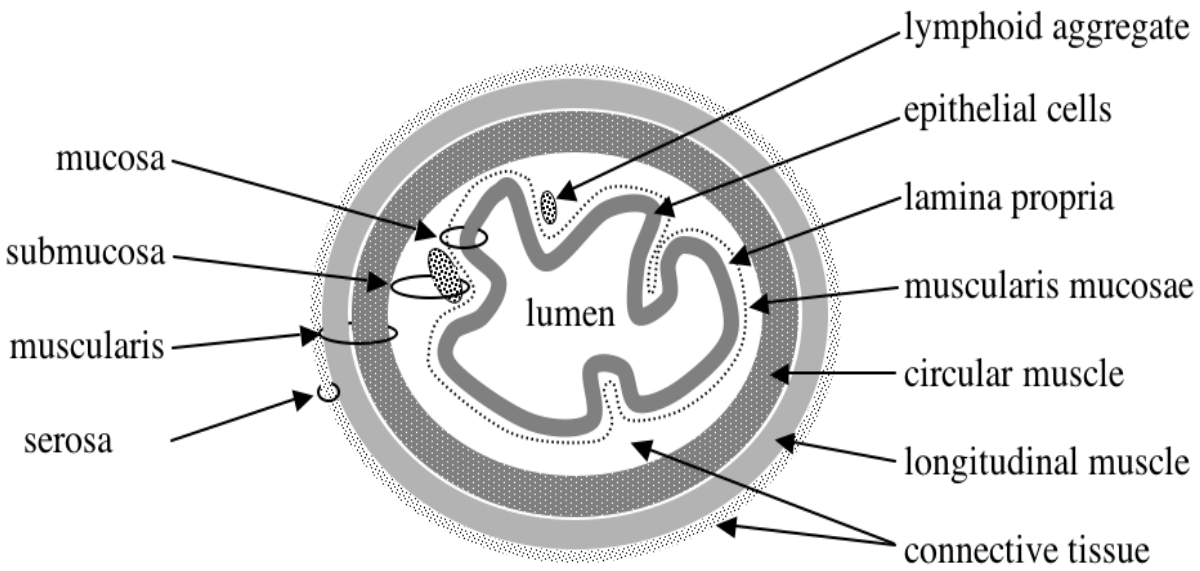

2.1. Stomach: normal – NDP Image: NHP2.1: 84.0159
Glass Slide: NHP2.1: 84.0159

The stomach is a dilated part of the gastro-intestinal tract. The stomach wall follows the general structure shown above, with some additions and modifications. The mucosa is thrown into prominent folds named rugae. The mucosa contains gastric glands into which mucous, acid and pepsin are secreted.

2.2. Small intestine: normal – NDP Image: NHP2.2: 88.685
Glass Slide: NHP2.2: 88.685

The small intestine is specialised for the absorption of digestion products, but conforms to the general structure shown in the diagram above. To increase the surface area for absorption, finger-like processes (**villi**) project into the lumen. The

villi are lined with a simple columnar epithelium. The most common cells in this epithelium are **enterocytes** (specialised for absorption) and **goblet cells** (have a clear appearance, specialised to produce mucous). Between the villi are numerous **crypts of Lieberkuhn** (often simply called **crypts** or **glands**) which produce a continuous supply of new epithelial cells that migrate up the villi before being shed or dying.

2.3. Large intestine: normal – NDP Image: NHP2.3: 60.1087
Glass Slide: NHP2.3: 60.1087
Image Map: N_AR_LI_01

The large intestine conforms to the general structure shown in the diagram above. However, it lacks villi and consists of closely packed straight tubular **glands** or crypts (test tube-shaped) that are analogous to the crypts of the small intestine. As in the small intestine, the epithelium contains a mixture of **enterocytes** and **goblet cells**.

2.4. Appendix: normal – NDP Image: NHP2.4: 76.554
Glass Slide: NHP2.4: 76.554
Image Map: N_AR_AP_08

The appendix is a small blind-ended sac that conforms to the general structural principles shown in the diagram above. It has no known absorptive or digestive function in man. In the appendix of a young person the lamina propria contains prominent **lymphoid aggregates**.

2.5. Liver: normal – NDP Image: NHP2.5: 97.220
Glass Slide: NHP2.5: 97.220
Image Map: N_AR_LV_02

The liver develops during embryogenesis as an outgrowth of the gut. The principle cells of the liver are **hepatocytes**. To maximise their contact with the blood flowing through the liver, hepatocytes are arranged into roughly hexagonal **lobules**. Blood within the portal vein and hepatic artery enters at the corners of the hexagonal lobules, and percolates through a network of **sinusoids** past the hepatocytes to reach a **central vein** in the centre of each lobule. At the corners of the lobules a portal vein branch, hepatic artery branch and bile duct branch run together surrounded by connective tissue and this is called a **portal triad**.

2.6. Kidney: Normal – NDP Image: NHP2.6: 79.475
Glass Slide: NHP2.6: 79.475
Image Maps: N_UR_KD_09 (a glomerulus)
N_UR_KD_06 (a nephron)

The kidney can be divided into an outer darkly staining **cortex** and an inner lightly staining **medulla**. The cortex contains numerous knot-like **glomeruli** (clusters of capillaries) and the blood vessels (afferent and efferent arterioles) that supply them.

In the glomeruli, fluids from the capillaries are filtered into the surrounding space (Bowman's capsule) and then flow into the epithelial-lined **renal tubules** (proximal convoluted tubule, loop of Henle & distal convoluted tubule – but these are difficult to distinguish histologically). In the medulla, the distal convoluted tubules coalesce into collecting ducts and eventually into the renal pelvis leading to the ureter that exits the kidney.

2.7. Thyroid: normal – NDP Image: NHP2.7: 58.5
Glass Slide: NHP2.7: 58.5
Image Map: N_NE_TH_02

The thyroid is an **endocrine gland** (also derived as an outgrowth of the gut tube during embryogenesis) that produces the hormones thyroxine, tri-iodothyronine (T4 and T3) and calcitonin. The thyroid stores the T3 and T4 hormone precursors as homogenous **thyroid colloid** within spheroidal **follicles**. The follicles are lined with a single layer of cuboidal epithelial cells. Adjacent C cells (almost impossible to see without special stains) produce calcitonin.

2.8. Cerebrum (brain): normal – NDP Image: NHP2.8: 95.579
Glass Slide: NHP2.8: 95.579
Image Map: N_NE_BR_01

The cerebrum is made up of an outer layer of **grey matter** (containing **neurone cell bodies** and supporting **neuroglial cells**) and an inner central core of **white matter** (containing tracts of **nerve fibres** among supporting neuroglial cells). The cerebrum is covered by a set of membranes known as the **meninges** which contain blood vessels.

Museum Specimens

I Appendix: Normal - **P83.794** & **81.466**
II Liver: Normal - **P83.636**
III Kidney: Normal - **P83.527** & **P85.701**

3.0. Tidying up

Before leaving:
Please make sure the desktop is switched to Pathology Pt1B folder on the PC.
Dim and switch off your microscope light.
Return the wooden block, if used.
Cover the microscope.
Push your stool under the bench.

Thank you!