NST Part 1B **Thurs 6th Oct 2016**

Pathology Practical Class NHP1 **Introduction to Normal Histology 1**

1.0. Aim

The overall aim of the practical classes is to help you understand the biological processes that lead to disease. One of the most satisfying aspects of these classes can be your discovery (by yourself rather than being shown) of the cell and tissue changes associated with a disease. To do this you will examine histological sections either with a microscope or with a computer using scanned image files of histological sections. For those who are not familiar with the microscopic appearances of healthy tissues, the discovery of disease-associated changes can be difficult.

The aim of these two introductory classes is to familiarise you with the histological appearances of healthy tissues so you will more easily be able to find disease-associated changes.

In all classes, sections of healthy tissues that correspond to the diseased tissues you are examining will always be available at the end of your bench for comparison.

2.0. Using your microscope

It is very important that you know how to use the microscope properly and feel comfortable using it. The following brief instructions will help. If you are uncertain about how to use the microscope, or you have difficulty in obtaining a clear image of a slide, please ask either a demonstrator or the classroom staff for assistance.



(1) If you are tall, put a wooden block under the microscope so that you are more comfortable. (There are wooden blocks on the side of the screen which is near bench F).

(2) Before switching on the light, ensure that:-

(i) Light intensity is at minimum
(ii) Low power (x4) objective is in position
(iii) Condenser is at upper 'stop' position
(iv) Stage is at the **lower** "stop" position [use coarse (larger) focus knob]

(3) Switch the light on and then increase the light intensity. If the image is too dark even with the light control at maximum, check the aperture diaphragm of the condenser underneath the slide. It may be closed right down (lever to the right). Move the lever to the left.

In general, use the light at the lowest comfortable setting. Please turn the light on and off at low intensity. Always turn it down to the minimum before switching off. Place a section under the microscope. Achieve a well-focused image with one eye using the x10 objective (orange/yellow) lens using the coarse and fine adjustment knobs.

(4) Adjust the distance between the eye-pieces for comfortable binocular vision and note the reading this gives on the central scale. Correct each eye-piece scale to the same reading and then focus accurately. (You may find you have to re-adjust one of the eye-pieces if your eyes are of unequal focal length).

(5) Changing objective lenses

There are four objectives:

x4 - red (low power objective)
x10 – orange/yellow (medium power objective)
x40 – green/blue (high dry objective)
x100 – blue/black & white (oil-immersion objective). It is rarely necessary to use this objective.

Secure a well-focused image with the x40 objective using the coarse and fine adjustment knobs. Then turn to the x4 objective and adjust the focus with the eye-pieces only. Thereafter, little adjustment should be required on changing from one objective to another.

The oil-immersion (x100) objective: Use only when **absolutely necessary** with a very small drop of oil. Do not allow the oil to get on any other objective lens.

Having selected a field with the x40 (high dry objective), turn the nose-piece to the low power (highest above the slide) so you can place the drop on the slide. Now gently swing the oil-immersion objective into the oil. The field will not be in exact focus, so you will have to use the fine focus with great care.

Afterwards, turn the nose-piece in the reverse direction, so the low power objective is again high over the oil. Do not accidentally bring the x 40 objective into the oil as you do this. Remove the slide gently and wipe it with a tissue but use lens paper to remove the oil from the oil objective. This should prevent the oil from being transferred to the high dry objective.

3.0. Interpretation of Pathological Processes

3.1. Looking at Tissue Sections

Before starting to look at the sections illustrating injury, death and Acute Inflammation, read the notes on Interpretation of Pathological Process. These notes will also be provided in future classes to help guide you in making deductions about Pathological Processes and also in Writing Reports.

(1) Look at the section with the naked eye first against a white background. See if you can identify distinct areas? If so, note their overall shapes, e.g., circular/wedge/cone, distributions, patchy, general and size.

(2) Look at the section with the low power objective. Scan across the section from one edge of the tissue to the other in order to get an overall impression of the different areas and identify patterns of cells.

(3) Using a higher power objective (x10, then x40) home in on representative areas of normal appearance or very abnormal looking regions. At this stage, try to identify cellular and other details. Always return to low power to finish scanning the section, drawing a sketch at low power and interpreting the overall picture at low power.

(4) If you can't remember what the normal tissue should look like, have a look at the edge of the section. Often there are small residual areas of normal tissue there.

Microscope sections present two-dimensional images, harvested in a moment of time, from three-dimensional tissues in which dynamic processes are going on continuously. Sections contain a great deal of information about such processes, but skill and caution are required to extract it appropriately.

3.2. Observe the following

(1) Distinguish the **parenchymatous** from the stromal elements in the tissue represented.
Parenchyma is an umbrella term for the main functional cell type in the tissue – hepatocytes in the liver, cardiac-type muscle in the heart, secretory epithelium in the intestinal glands. Stroma in a tissue is the equivalent of service ducting in a building, and consists of fibroblasts and the collagen they produce, blood vessels, fine nerve bundles and sometimes adipose tissue. Each of these has a characteristic appearance in a section, which you should learn to recognise. Stroma is often called connective tissue.

(2) From the appearance of the parenchymatous element, try to determine which organ you are studying. Sometimes this information will be given, but you can still identify clues in the section as to its exact original whereabouts. Thus, does your section of lung come from the periphery of the organ (plentiful alveolar spaces, only small respiratory passages, perhaps also a pleural surface), or from nearer the centre (larger bronchi and blood vessels, possibly lymph nodes)?

(3) Determine if the tissue reveals the presence of a pathological process. Look for neutrophils, macrophages and lymphocytes in substantial numbers outside of blood vessels, as indicators of inflammation. In sections stained with haematoxylin & eosin, as most of yours will be, the nuclei of these migrating cells appear as dark-blue dots peppering the section. As you will find later, tumour growth also has the effect of producing a clustered excess of cells (with blue nuclei), but this time they bear a crude similarity to the normal cells from which they arose. In contrast, in necrosis the dead tissue appears as sheets of formless, pink material, the nuclei of the dead cells having been destroyed.

(4) Bearing all this in mind, first, look with the naked eye; then scan the section at low power. Make sure you do not miss out any part of the section. Once you have scouted out the whole territory covered by the section, swoop down selectively on areas that interest you, using the higher power lenses (professional pathologists never scan whole sections with the high power lens). Compare the appearances of the sections given with sections from corresponding normal tissue. These are sometimes also given, but there are always examples in a box at the end of your bench.

	Colour of stain	Terminology	Examples
Haematoxylin	Blue/purple	Basophilic (Haematoxyphilic)	Nucleic acids, eg. DNA of nucleus RNA of ribosomes All bacterial clumps
Eosin	Pink	Acidophilic (Eosinophilic)	Proteins, eg. Cytoplasmic proteins Extracellular matrix proteins Deposited plasma proteins

4.0. Scanned Digital Slide Images of Tissue Sections: View Using Omero

Instructions for use can be found here:
http://www.openmicroscopy.org/site/products/omero

5.0. What is a tissue section?

The tissues sections you will observe in these classes have been made by fixing a small fragment of tissue in formalin to preserve the tissue structure. This fragment is then embedded in paraffin wax, which allows it to be thinly sectioned (sliced) and placed on a microscope slide. The sections you will look at in the introductory classes have been stained with a combination of two dyes: Haematoxylin stains the DNA and RNA within the cell blue/purple, and Eosin stains proteins within and outside the cells pink. Note that it is extremely difficult to obtain identical staining on every slide, so you will become used to observing slides where the strength of eosin and haematoxylin staining varies. Microscope sections present two-dimensional images, harvested in a moment of time, from three-dimensional tissues in which dynamic processes are going on continuously.

6.0. The basic structures of cells

Cells are the fundamental units of living organisms. In the tissues you will be observing they are approximately 10 uM (1/100th of a mm) in size. Cells are bounded by a plasma membrane. Within this the pink-staining cytoplasm is visible which contains the cellular organelles including the blue-staining nucleus. Often details can be seen within the nucleus such as the nucleolus and chromatin clumps. A good web site to review the basics of cells is http://www.cellsalive.com/index.htm. An excellent web site covering normal tissue histology is provided by Dr Teresa Tiffert at the Cambridge University Department of Physiology, Development & Neurosciences

http://www.pdn.cam.ac.uk/teaching/resources/1a_histology/index.shtml

7.0. Observation of sections of healthy tissues

7.1. Blood: Normal Slide – NDP Images: NHP1.1, 86.547 & 96.354
Glass slide: NHP 1.1: 86.547 & 96.354
Image Map: N_HL_BF_14, N_HL_BF_09 & N_HL_BF_03

The easiest cells to examine are those that can be observed separately, such as the cells found in blood. This slide of normal blood will introduce you to a wide variety of normal cells.

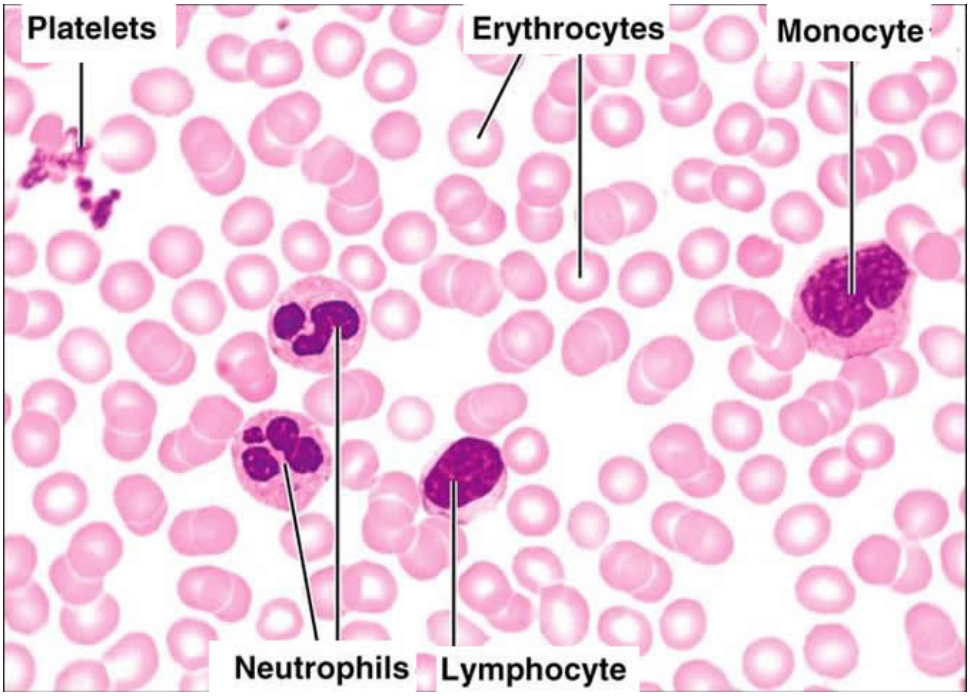

The most common cells on this slide are red blood cells (erythrocytes). These are small cells with a bi-concave cytoplasm. They lack nuclei.

Most of the remaining cells are white blood cells (leukocytes). The size, shape and staining of the nuclei and cytoplasmic organelles varies greatly between leukocyte types.

For example;
Monocytes often have a round or kidney-shaped nucleus and a large pale blue cytoplasm.

Neutrophils have a multi-lobed nucleus (often 3-4 lobes)

Lymphocytes have a large darkly-staining nucleus (with only a thin rim of cytoplasm that is difficult to see in some lymphocytes).

7.2. Uterus: Normal - NDP Images: NHP1.2: 66.217 & 66.218
Glass Slides: NHP1.2: 66.217 & 66.218
Image Map: N_UR_UT_03

The uterus provides an excellent example of a solid organ containing a variety of tissues with different cell types.

The cells within solid tissues can be divided into; (i) the main functional cell type (known as parenchymal cells or parenchyma) and (ii) supporting cells (known as stromal cells or stroma). The stromal cells include fibroblasts, blood vessels, nerve bundles, cells of the immune system such as macrophages, and sometimes adipose tissue. Tissues containing predominantly stromal cells are often called connective tissue. The stromal and parenchymal cells signal to one another – these signals regulate the survival, division, migration and differentiation of each cell as well as the overall structure of the tissue.

In the uterus the division between parenchymal and stromal cells is easy to observe. The layer of the uterus closest to the lumen of the uterus is known as the endometrium. This contains glands that open onto the surface. The surface of the endometrium and the glands are lined with epithelial cells – these form the parenchyma of this tissue. Underlying and supporting the epithelial cells is a network of many cell types that forms the stroma (endometrial stromal cells are spindle shaped with dark blue nuclei). Beneath these stromal cells is the muscular outer layer or wall of the uterus – the myometrium (made of spindle shaped smooth muscle cells). With help from your demonstrators try to identify these features on the slide.

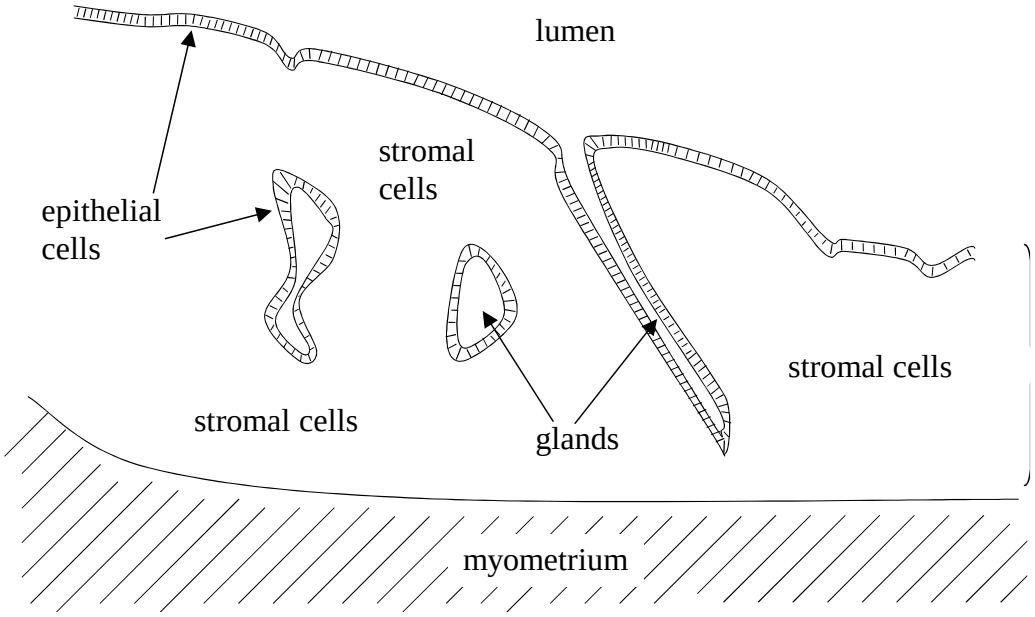

7.2. NHP1.2A - Normal Adult Uterine Cervix: UG7
NDP Images: NHP1.2A: 82.74 & 87.1081
Glass Slides: NHP1.2A: 82.74 or 87.1081 (which shows one side of the endocervical canal only).
Image Map: N_UR_CX_02 & N_UR_CX_11

Find the squamo-columnar junction, which is where the single-layered, columnar glandular epithelium that lines the endocervical canal of the uterus meets the squamous epithelium of the ectocervix (the part that projects into the vagina). Note how sharp and distinct the boundary can be. The region of the cervix where the squamo-columnar junction occurs is often known as the transformation zone.

7.3. Artery: Normal – NDP Images: NHP1.3: 83.231
Glass Slides: NHP1.3: 83.231
Image Map: N_CR_AY_11 & N_CR_AY_14

Arteries are made up of 3 concentric cell layers (called tunica). In contact with the lumen are the thin flattened endothelial cells. Beneath these is a springy layer of protein called an (internal) elastic lamina. Together these inner layers of artery walls are known as the tunica intima (or the intima for short). Surrounding the tunica intima are layers of smooth muscle cells known as the tunica media (forming the muscular wall of the artery). Covering the external surface of the artery is another (external) elastic lamina and a layer of connective tissue. Together these outer layers are the tunica adventitia. The simplified structural layers of a muscular artery are shown below.

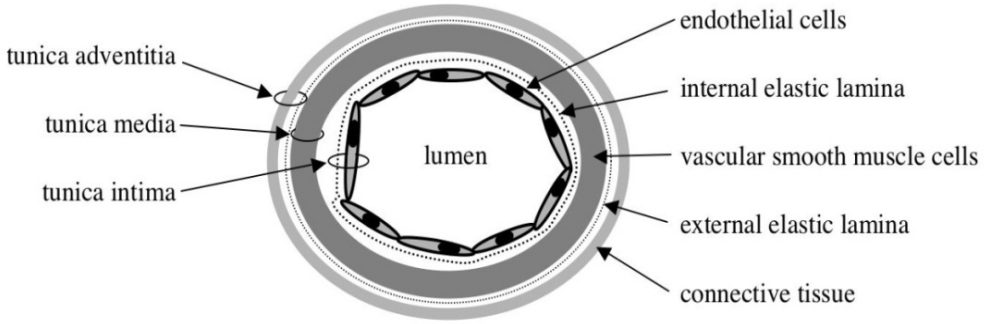

7.4. Heart, myocardium: Normal – NDP Image NHP1.4: 84.158
Glass Slide: NHP1.4: 84.158
Image Map: N_CR_HT_03 & N_CR_HT_02

Like arteries, the heart is lined with endothelial cells. This endothelial layer is known as the endocardium. The cardiac muscle cells above these endothelial cells form the myocardium. Cardiac muscle cells are specialized elongated striated muscle cells containing centrally placed nuclei. Their appearance varies depending on whether the muscle cells are cut in longitudinal or transverse section. The myocardium is surrounded by a layer of connective tissue known as the epicardium (analogous to

the tunica adventitia of blood vessels, often with fat cells). The epicardium is covered with a layer of a lubricated membrane known as the pericardium.

7.5. Lung: Normal – NDP Image: NHP1.5: 70.16A
Glass Slide: NHP1.5: 70.16A
Image Map: N_CR_LU_02 & N_CR_LU_08

Most of the lung is made up of thin-walled air sacs known as alveoli. These are supplied with air by small bronchioles, which are in turn supplied by bronchi that are fed from the trachea. To allow gas exchange, the alveoli are supplied with blood from the right ventricle of the heart through the pulmonary vessels. The lungs also have a second, accessory blood supply from the aorta known as bronchial arteries.

Museum Specimens

I Heart: Normal - P80.825 & P83.250
II Lung: Normal - P82.291

8.0. Tidying up

Before leaving:
Please make sure the desktop is switched to Pathology Pt1B folder on the PC.
Dim and switch off your microscope light.
Return the wooden block, if used.
Cover the microscope.
Push your stool under the bench.

Thank you!